

Treatment of peri-implantitis and guided bone regeneration associated with autogenous bone: A case report

Abstract / Introduction: Dental implants have been considered important allies in the rehabilitation treatment of lost teeth, either in single-unit cases or in more complex rehabilitations. However, adverse outcomes may occur, for instance, peri-implantitis, which is an infectious disease similar to chronic periodontitis, affecting peri-implant tissues of which treatment aims at restoring health, as well as function and esthetics. Most treatments focus on reducing the microbiological burden of the peri-implant environment pocket by decontaminating the implant surface. In many cases, treatment of infection is followed by bone regeneration with fairly good results. Several treatment protocols have been suggested, however, little is yet known whether these therapies are able to lead to new osseointegration of implants. **Objective:** The aim of this case report was to show some aspects of peri-implantitis with emphasis on its treatment, and to show the outcomes of associating autogenous bone graft with guided bone regeneration. Our results reveal that the association between both techniques might result in high bone gain rates and complete implant cover. **Keywords:** Dental Implants. Periodontitis. Peri-implantitis.

Celso Renato de Souza RESENDE
PhD in Materials Sciences, Military Institute of Engineering (IME).

Luis Paulo Diniz BARRETO
Masters student in Periodontology, University of Grande Rio (UNIGRANRIO).

Léo Guimarães SOARES
PhD in Dentistry, State University of Rio de Janeiro (UERJ).

Denise Gomes da SILVA
Assistant Professor, Department of Dentistry, UNIGRANRIO.

Márcio Eduardo Vieira FALABELLA
Assistant Professor, Department of Dentistry, UNIGRANRIO and Federal University of Juiz de Fora (UFJF).

How to cite this article: Resende CRS, Barreto LPD, Soares LG, Silva DG, Falabella MEV. Treatment of peri-implantitis and guided bone regeneration associated with autogenous bone: A case report. *Dental Press Implantol.* 2014 July-Sept;8(3):58-63. doi: <http://dx.doi.org/10.14436/2237-650X.8.3.058-063.oar>

Submitted: October 21, 2013 - **Revised and accepted:** August, 20, 2014

Contact address: Léo Soares
Praça Garcia, 99 – Centro – Paraíba do Sul/RJ – Brazil – CEP 25850-000

» The authors report no commercial, proprietary or financial interest in the products or companies described in this article.

» Patients displayed in this article previously approved the use of their facial and intraoral photographs.

INTRODUCTION

Osseointegration has enhanced the therapeutic arsenal for the treatment of various forms of edentulism and periodontal problems. A prerequisite for the success of endosseous dental implants is the achievement and maintenance of a peri-implant mucosa on the soft tissues around implants.¹

Osseointegration is defined as the process by which rigid and clinically asymptomatic fixing of alloplastic material is performed and maintained in bone during functional loading.² Bone loss occurs in the stages of healing, during the functional loading of implants, and as a result of bacterial colonization on the implant surface whenever it is exposed to the oral cavity. It also occurs during the bone remodeling process as a result of occlusal loading. Importantly, implant placement failure may be assigned to primary causes (improper surgical technique, failure to achieve osseointegration and early loading) or secondary causes (marginal infection peri-implantitis, biomechanical overload or a combination of both).³

Peri-implantitis is an inflammatory reaction established in the tissues surrounding an implant, which may result in loss of supporting bone and eventually lead to implant placement failure.⁴ Peri-implant mucositis corresponds, in basic terms, to gingivitis. It has been defined as a reversible inflammatory reaction established in the peri-implant mucosa around osseointegrated dental implants.⁵ The prevalence of peri-implantitis is not yet well established. It ranges from 2% to 10% and may lead to implant failure and loss.⁶

Diagnosis of peri-implantitis is based on classic periodontal parameters: probing depth, changes in the level of implant placement or absence of marginal bone loss.⁷ Clinical signs such as bleeding gingiva, edema, and, at a later phase, bone loss, greatly resemble periodontal

inflammation.⁸ Purulent secretion is also common in cases of peri-implantitis.⁹ Although the clinical features of peri-implantitis are very similar to those of periodontitis, the histopathological characteristics of both types of lesions seem to differ widely.¹⁰

Dental plaque is considered to be the primary etiologic factor of tooth and implant loss. Destruction of peri-implant tissues is due to accumulation of bacteria with potential for periodontal tissue destruction.⁶ On the other hand, some authors claim that microorganisms not normally associated with periodontitis, such as *Staphylococcus spp*, *Enterobacteriaceae* and *Candida spp.*, could also play a role in peri-implantitis.¹¹

Periapical radiographs are essential to assess marginal bone loss and diagnose interproximal bone loss; however, panoramic radiographs tend to present with higher distortion.¹²

Strategic treatment of implant complications and failure is influenced by the identification of potential etiologic factors, and basically consists of basic therapy, reduction of masticatory stress and surgical procedures (non-surgical, involving resection or regeneration).¹³ The process of applying the principles of Guided Tissue Regeneration (GTR) in Implantology is also known as Guided Bone Regeneration (GBR), and the results achieved during healing will depend on the origin of cells replacing the surgical wound.¹⁴

Therefore, this study aimed at presenting some aspects of peri-implant disease by means of a case report of which emphasis was given on treatment combining autogenous bone graft and guided bone regeneration.

CASE REPORT

This study reports the case of a 50-year-old, male patient with advanced chronic periodontitis and no systemic disease. Initial clinical

examination revealed the presence of bleeding on probing and bone loss greater than 2/3 of the length of implants replacing teeth #46 and 47, thereby arriving at the diagnosis of peri-implantitis (Fig 1). Once initial basic periodontal therapy had been carried out, the patient was medicated with Amoxicillin 500 mg, 1.5 g / day, starting two days before surgery, and maintenance for seven days. The patient had peri-implant pockets with depth greater than 10 mm and 3 mm after treatment.

The surgical procedure was performed under local debridement, use of abrasive blasting and topical application of tetracycline HCl used as an adjunct to disinfect the surface of the implant placed in the region of tooth #47. The implant placed in the region of tooth #46 was removed due to presenting mobility, whereas three other implants were placed in the region of teeth #46, 45 and 44 immediately after extraction of compromised teeth. The implants corresponding to teeth #45 and 46 remained with threads exposed above the bone crest due to being too near the inferior alveolar nerve (Fig 2). They were regenerated by means of guided bone regeneration with autogenous bone. Autograft bone was harvested from the retromolar area with the aid of a scraper. It covered the implant threads where they were located above the bone level (Fig 3). An aluminium oxide layer (Maxtron) was used as a barrier for the GBR technique (Fig 4). Implants and platforms used were regular and 13.0 mm in length, Master Screw (Conexão), had undergone Dhabi abrasive blasting with its respective abrasive powder Tetracycline 50 mg / ml. The membrane was not exposed during this period, and 0.12% chlorhexidine gluconate was prescribed.

The reentry surgery was performed 11 months later and showed a high rate of bone

tissue gain around implants, including the implant placed in the region of tooth #47, which had peri-implantitis confirmed by clinical and radiographic examination (Fig 5).

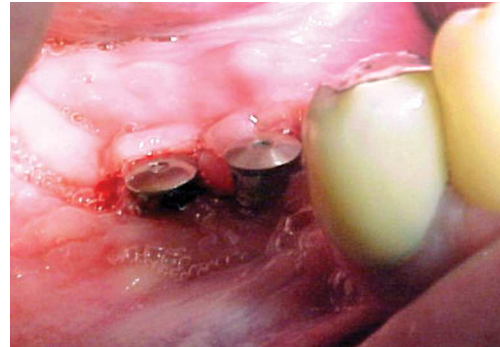


Figure 1. Initial photograph.

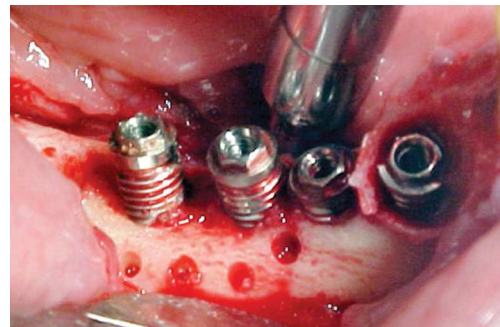


Figure 2. Implants #44, 45 and 46 installed.

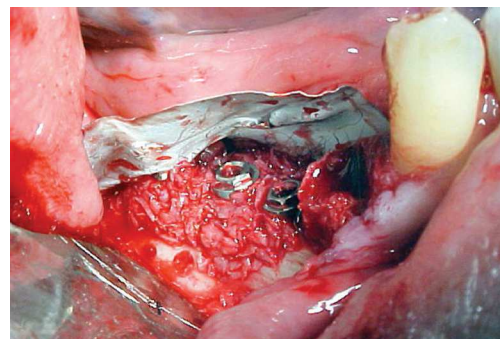


Figure 3. Placement of autogenous bone harvested from the retromolar area with the aid of a scraper.

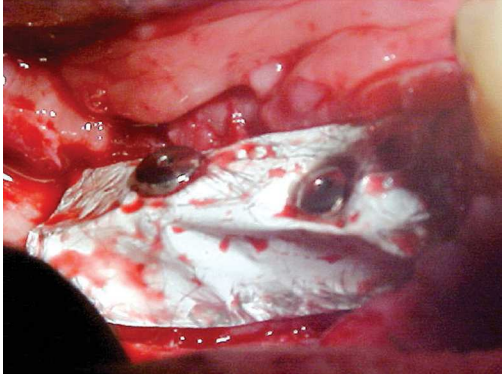


Figure 4. Fitting an aluminum oxide membrane for the technical application of GBR.

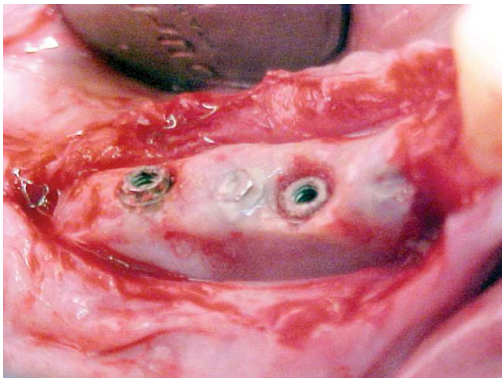


Figure 5. Reentry surgery after 11 months.

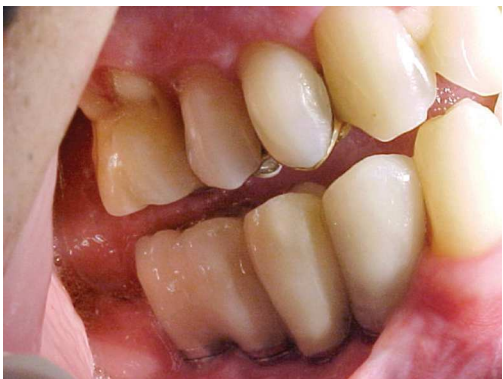

Figure 6. Final prosthesis installed three months after reentry surgery (14 months).

The final prosthesis was installed three months after reentry (Fig 6). The implants remain in function for more than 7 years. Denture was installed 8 months after reopening.

DISCUSSION

Peri-implantitis consists of tissue inflammation around implants associated with bone loss.^{6,15} It is suggested that implants be assessed on the basis of classical clinical periodontal parameters.^{6,7} However, there is serious doubt about the importance of considering peri-implant bleeding after probing as an appropriate parameter to diagnose peri-implant disease.¹⁶ In the case described herein, diagnosis was made based on the sites where depth and bleeding on probing were suggestive clinical findings.⁷

No consensus has been reached among practitioners and researchers with regard to the best technique to treat peri-implantitis. The results achieved during the healing process depend on the origin of the cells replacing the surgical wound. Cases in which peri-implant bone support has been lost in more than half of the length of the implant, implant removal should be contemplated.^{6,7} Cases of GTR failure were associated with the presence of residual periodontal pathogens.¹⁷

Studies¹⁸⁻²⁰ on nonsurgical medical treatment of peri-implantitis showed that in a control of 6-12 months, there was a reduction in suppuration and bleeding on probing, but there was no significant reduction in probing depth, which favored the initial condition of the disease to relapse. These results suggest that nonsurgical treatment alone is not enough to recover peri-implant health.

Even though implant treatment is not contraindicated for individuals with a history of periodontitis, patients should be informed about the increased risk of loss, since

the number of failures remains high, as it is the case of smokers.²¹

Pre surgical antibiotic therapy (Amoxicillin + Metronidazole) is highly recommended, with Amoxicillin 1.5 g / day two days before surgery and seven days after surgery. In the case reported herein, Amoxicillin was used following the protocol suggested.²³

The implant placed in the region of tooth #46 was removed due to presenting mobility and bone loss, which is in agreement with studies⁶ suggesting implant removal under these conditions. Previous decontamination of the implant surface involved in peri-implantitis is highly recommended. It should be carried out by means of abrasive blasting and chemical substances, such as tetracycline²³ and citric acid,²⁴ both of which have been used to assist in the removal of toxic bacterial products and in the attempt to “reactivate” the desirable biological properties of the surface layer of titanium dioxide.¹⁸ Besides mechanical debridement, abrasive blasting and topical application of tetracycline HCl were used around the implant placed in the region of tooth #47 tooth with the aforementioned objectives.

No decontamination method has yet been accepted as the gold standard.²⁵ Decontamination of the implant surface is a feature of most studies; however, to date, no method of surface decontamination has proved superior.²⁶

This case was regenerated by means of the membrane technique suggested in protocol.²⁷ Guided bone regeneration has been suggested to restore lost bone tissue and is considered a technique that can be successfully used in cases of peri-implantitis.¹⁴ The use of GBR for treatment of bone loss caused by peri-implantitis leads to satisfactory results, whether with graft material associated to the membrane or not.²³ Maintenance of the framework

is crucial. In this scenario, autogenous bone favors maintenance of the framework and adds growth factors and cells, depending on the type of autograft used. This procedure enhances bone gain, especially when vertical gain is desired,¹⁴ thereby justifying the use of autogenous bone in the case described herein. Aluminum oxide membrane was chosen due to providing a good framework, thus preventing invagination of the membrane into the space beneath it. The combination of autogenous bone and an aluminum oxide membrane yielded good clinical outcomes not only around new implants, but also around the implant with peri-implantitis.^{14,28}

A study²⁹ compared two surgical therapies for the treatment of peri-implantitis: resection surgery using chisels, disinfection with 25% metronidazole gel, tetracycline solution 50 mg / ml and saline solution *versus* the same therapy associated with implantoplasty. The therapy involving removal of the implant screw (implantoplasty) after two years of follow-up presented superior, statistically significant results with regard to clinical, supra and subgingival parameters. In the present study, there was a high incidence of gingival recession, which is explained by the discrepancy between the values of probing depth and clinical attachment level. Another aspect to be noted is the lack of information about the possible consequences of the use of drills for implants, including heat and extreme surface modification, which must be carefully considered when recommending this technique.

CONCLUSION

Treatment combining peri-implantitis based on the decontamination of the implant surface associated with the use of guided bone regeneration resulted in bone gain.

REFERENCES:

- Salcetti JM, Moriarty JD, Cooper LF, Smith FW, Collins JG, Socransky SS, et al. The clinical, microbial, and host response characteristics of the failing implant. *J Oral Maxillofac Surg.* 2007;65(7 Suppl 1):13-9.
- Albrektsson T, Zarb G, Worthington P. The long-term efficacy of currently used dental implants. A review and prognosis criteria for success. *Int J Oral Maxillofac Implants.* 1986;1(1):11-25.
- Klokkevold PR, Newman MG. Current status of dental implants: a periodontal perspective. *Int J Oral Maxillofac Implants.* 2000;15(1):56-65.
- Fransson C, Tomasi C, Pikner SS, Grondahl K, Wennstrom JL, Leyland AH, et al. Severity and pattern of peri-implantitis-associated bone loss. *J Clin Periodontol.* 2010;37(5):442-8.
- Nogueira Filho G, Iacopino AM, Tenenbaum HC. Prognosis in implant dentistry: a system for classifying the degree of peri-implant mucosal inflammation. *J Can Dent Assoc.* 2011;77:b8.
- Mombelli A, Lang NP. The diagnosis and treatment of peri-implantitis. *Periodontol* 2000. 1998;17:63-76.
- Steenberghe VD, Quirynen M, Callens A. The reactions of periodontal tissues to implants and teeth. In: Laney WW, Tolman DE. *Tissue integration in oral, orthopedic e maxillofacial reconstruction.* Hanover Park: Quintessence; 1990. p. 41-7.
- Sahrman P, Attin T, Schmidlin R. Regenerative treatment of peri-implantitis using bone substitutes and membrane: a systematic review. *Clin Implant Dent Relat Res.* 2011;13(1):46-57.
- Lang NP, Berglundh T. Peri-implant diseases: where are we now? Consensus of the seventh European workshop on periodontology. *J Clin Periodontol.* 2011;38(Suppl 11):178-81.
- Carcuac O, Abrahamsson I, Albouy JP, Linder E, Larsson L, Berglundh T. Experimental periodontitis and peri-implantitis in dogs. *Clin Oral Impl Res.* 2013;24(4):363-71.
- Kronström M, Svenson B, Hellman M, Persson GR. Early implant failures in patients treated with Branemark System titanium dental implants: a retrospective study. *Int J Oral Maxillofac Implants.* 2001;16(2):201-7.
- Algraffee H, Borumandi F, Cascarini L. Peri-implantitis. *Br J Oral Maxillofac Surg.* 2012;50(8):689-94.
- Esposito M, Hirsch J, Lekholm U, Thomsen P. Differential diagnosis and treatment strategies for biologic complications and failing oral implants: a review of literature. *Int J Oral Maxillofac Implants.* 1999;14(4):473-90.
- Quinones CR, Caffesse RG. Current status of guided periodontal tissue regeneration. *Periodontol* 2000. 1995;9:55-68.
- Gomes REE. Peri-implantite [trabalho de conclusão de curso]. Rio de Janeiro (RJ): ABO; 1998.
- Adonogianaki E, Mooney L, Wennstrom L, Lekholm U, Kinane DF. Acute-phase proteins and immunoglobulin G against *Porphyromonas gingivalis* in peri-implant crevicular fluid: a comparison with gingival crevicular fluid. *Clin Oral Implants Res.* 1995;6(1):14-23.
- Schwarz F, Sahn N, Bieling K, Becker J. Surgical regenerative treatment of peri-implantitis lesions using a nanocrystalline hydroxyapatite or a natural bone mineral in combination with a collagen membrane: a four-year clinical follow up report. *J Clin Periodontol.* 2009;36(9):807-14.
- Persson GR, Samuelsson E, Lindahl C, Renvert S. Mechanical non-surgical treatment of peri-implantitis: a single-blinded randomized longitudinal clinical study. II. Microbiological results. *J Clin Periodontol.* 2010;37(6):563-73.
- Sahn N, Becker J, Santel T, Schwarz F. Non-surgical treatment of peri-implantitis using an air-abrasive device or mechanical debridement and local application of chlorhexidine: a prospective, randomized, controlled clinical study. *J Clin Periodontol.* 2011;38(9):872-8.
- Winkelhoff AJ. Antibiotics in the treatment of peri-implantitis. *Eur J Oral Implantol.* 2012;5(Suppl):43-50.
- Heitz-Mayfield LJ, Huynh-Ba G. History of treated periodontitis and smoking as risks for implant therapy. *Int J Oral Maxillofac Implants.* 2009;24 Suppl:39-68.
- Ericsson I, Persson LG, Berglundh T, Edlund T, Lindhe J. The effect of antimicrobial therapy on peri-implantitis lesions. An experimental study in the dog. *Clin Oral Implants Res.* 1996;7(4):320-8.
- Höhn A, Ferreira CRF, De Mori R. Peri-implantite: relato de caso clínico. *Rev Bras Odontol.* 2001;58(2):102-4.
- Zablotsky M, Meffert R, Mills O, Burgess A, Lancaster D. The macroscopic, microscopic and spectrometric effects of various chemotherapeutic agents on the plasma-sprayed hydroxyapatite-coated implant surface. *Clin Oral Implants Res.* 1992;3(4):189-98.
- Ntrouka V, Hoogenkamp M, Zaura E, van der Weijden F. The effect of chemotherapeutic agents on titanium-adherent biofilms. *Clin Oral Implants Res.* 2011;22(11):1227-34.
- Claffey N, Clarke E, Polyzois I, Renvert S. Surgical treatment of peri-implantitis. *J Clin Periodontol.* 2008;35(6 Suppl):316-32.
- Dahlin C, Sennerby L, Lekholm U, Linde A, Nyman S. Generation of new bone around titanium implants using a membrane technique: an experimental study in rabbits. *Int J Oral Maxillofac Implants.* 1989;4(1):19-25.
- Schwarz F, Sahn N, Schwarz K, Becker J. Impact of defect configuration on the clinical outcome following surgical regenerative therapy of peri-implantitis. *J Clin Periodontol.* 2010; 37(5):449-55.
- Romeo E, Ghisolfi M, Murgolo N, Chiapasco M, Lops D, Vogel G. Therapy of peri-implantitis with resective surgery. A 3-year clinical trial on rough screw-shaped oral implants. Part I: clinical outcome. *Clin Oral Implants Res.* 2005;16(1):9-18.